

Impetigo Herpetiformis – A Rare Dermatosi s of Pregnancy Associated with Prenatal Complications

KS Lim,¹ MBBS, MRCP (UK), MBY Tang,¹ MBBS, MRCP (UK), M Med (Int Med), PPL Ng,¹ MBBS, MRCP (UK)

Abstract

Introduction: We describe a patient who developed an acute generalised pustular eruption associated with pyrexia at 33 weeks of gestation. **Clinical Picture:** Her condition was complicated by preterm labour, requiring an emergency caesarean section delivery. A diagnosis of impetigo herpetiformis was made on clinicopathological grounds. **Treatment:** Initial treatment with topical and systemic corticosteroids failed and oral methotrexate was added. **Outcome:** She responded well to this therapy and required only 2 doses of weekly methotrexate. **Conclusion:** Impetigo herpetiformis is a rare dermatosis of pregnancy that requires early recognition and treatment to prevent maternal and fetal morbidity. Combination therapy using oral corticosteroids and short-term methotrexate is effective.

Ann Acad Med Singapore 2005;34:565-8

Key words: Methotrexate, Pregnancy complications, Psoriasis, Pustule

Introduction

Impetigo herpetiformis (IH) is a rare dermatosis of pregnancy that can present dramatically in the third trimester of pregnancy with widespread cutaneous pustulosis and serious systemic features, including fetal distress.^{1,2} Early recognition of this condition is of utmost importance as maternal and fetal well-being may be compromised due to misdiagnosis and inappropriate treatment. This condition is often confused with other diagnoses such as pustular drug eruptions or bacterial skin sepsis. Clinicopathological correlation is essential for the diagnosis of this condition.

We report a case of IH presenting in a pregnant female that was associated with the premature rupture of membranes and fetal distress requiring emergency delivery. The patient's condition continued to progress in the immediate postpartum period and subsequently required systemic glucocorticoids and methotrexate for control.

Case Report

A 40-year-old female, gravida 3 para 2, presented at 33 weeks of gestation with a sudden, spontaneous onset of painful and itchy erythematous pustules that were initially localised over her inner thighs bilaterally. There were no new contactants or precipitating factors of note. There was

no prior drug history or ingestion of any supplements. The antenatal history was unremarkable up to the time of presentation. Her personal and family history was negative for skin diseases, including psoriasis. There was no development of any cutaneous eruptions in the previous 2 pregnancies.

Her attending obstetrician made an initial diagnosis of acute bacterial folliculitis and she received a course of intravenous erythromycin and cloxacillin for 1 week. Her rash initially appeared to stabilise and she was discharged with a course of oral antibiotics.

However, her rash continued to progress over the next 2 weeks, becoming generalised, affecting the rest of her body including her face, trunk and limbs. This was associated with a high fever with no chills or rigors.

Finally, at 36 weeks of gestation, her condition was complicated by the sudden premature rupture of membranes and fetal distress, requiring an emergency caesarean section. Apart from a low birth weight of 2.23 kg, her baby had no significant birth or neonatal complications.

In view of her extensive pustular eruption that was not responding to continuous systemic erythromycin and cloxacillin therapy, a dermatological opinion was sought post-delivery.

¹ National Skin Centre, Singapore

Address for Reprints: Dr Kar-Seng Lim, National Skin Centre, 1 Mandalay Road, Singapore 308205.

Email: kslim@nsc.gov.sg

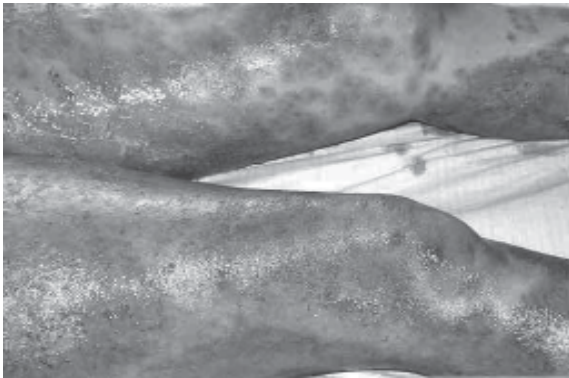

Fig. 1. Widespread erythematous plaques and erosions over the lower limbs of the patient.

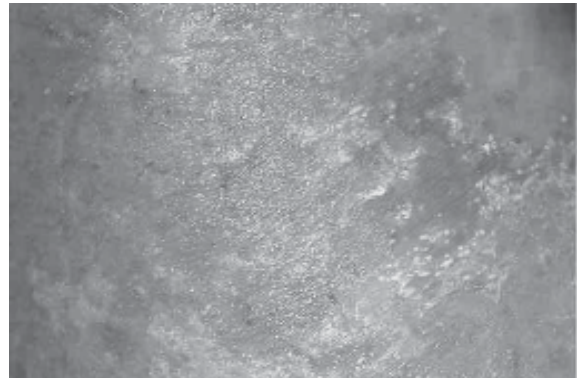


Fig. 2. Non-follicular pustules at the periphery of an erythematous plaque.

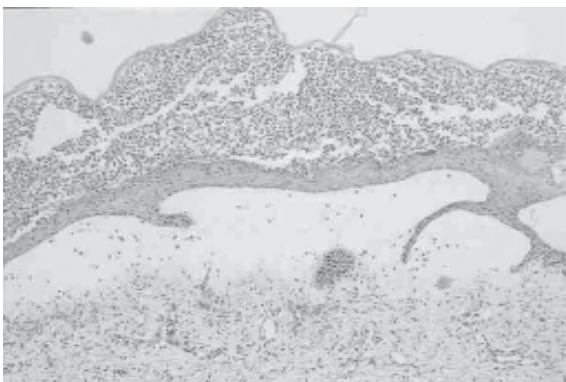


Fig. 3. Subcorneal pustules and exudates of neutrophils into upper epidermis. Note oedematous upper dermis (haematoxylin & eosin, x40).

Clinical examination revealed a patient who was febrile (maximum temperature 39°C) but clinically non-toxic, with stable vital signs. She had widespread erythematous plaques studded with non-follicular pustules (Figs. 1 & 2) involving around 80% of her body surface area, including her face, trunk and limbs. Some of the pustules over her limbs had become confluent, coalescing into larger pus-filled bullae. Several clear flaccid bullae were noted as well, arising from the erythematous plaques in an annular configuration. The mucosal membranes and eyes were not affected. There were no joint or nail abnormalities noted. The rest of the systemic examination was unremarkable except for an asymmetrical, painless swelling of her right calf. The initial impression was that of IH, pustular psoriasis or a drug-induced pustular eruption.

Skin histology from 2 sites showed subcorneal neutrophilic pustules and infiltration of neutrophils into the upper epidermis, forming spongiform pustules. The upper papillary dermis was oedematous with perivascular lymphocytes and neutrophils (Fig. 3). Direct immunofluorescence studies of perilesional skin were negative.

Significant laboratory findings were as follows: mild leukocytosis of $10.8 \times 10^9/L$ with significant neutrophilia of 88.5%; a raised erythrocyte sedimentation rate (ESR) of 129 mm/hour; severe hypoalbuminaemia of 19 g/L; a mildly depressed phosphate level of 0.71 mmol/L (normal 0.77 mmol/L to 1.38 mmol/L) and microcytic, hypochromic anaemia of 8.8 g/dL, which was consistent with previously diagnosed iron deficiency anaemia. The rest of her biochemistry, including serum calcium, renal and liver function tests, were within normal limits. Repeated bacterial cultures from her blood and skin were sterile. A Doppler ultrasound of her right calf was negative for deep vein thrombosis.

A diagnosis of IH was made on clinicopathological grounds and oral prednisolone 0.5 mg/kg body weight was commenced. Her rash and pyrexia did not improve and after 5 days of systemic and topical corticosteroid therapy, low-dose methotrexate 7.5 mg per week was added, after extensive discussion with the patient and her husband.

There were signs of clinical improvement by the end of the first week of combination therapy, with resolution of the pyrexia and cessation of new pustules. By the second week, her skin condition had improved significantly, with areas of desquamation and resolution of the inflammatory oedema over the affected areas.

Oral prednisolone was decreased gradually over 1 week. A total cumulative dose of 15 mg of methotrexate was given (7.5 mg weekly for 2 weeks). Her skin condition subsequently resolved completely with post-inflammatory hyperpigmentation. No further rebound or relapses were noted. At the last review 9 months post-delivery, she remained well with no new development of skin or nail problems.

Discussion

While the underlying aetiology and pathogenesis of IH is

still unknown,^{1,2} there is some debate as to whether this is a distinct dermatosis of pregnancy or a form of pustular psoriasis.³⁻⁵ As in this case, most patients do not have a personal or family history of psoriasis^{6,7} and do not subsequently develop chronic plaque psoriasis.^{5,7} Furthermore, the condition appears to resolve with the termination of the pregnancy, but it can recur in subsequent pregnancies.^{2,8,9} As such, we feel that these characteristics of IH suggest that it is a distinct dermatosis of pregnancy.

This case illustrates many classical presenting features of IH,^{1-3,5} such as the late onset in the last trimester of pregnancy; characteristic sterile pustules initially arising over the intertriginous areas with subsequent involvement of the trunk and limbs; the coalescing of lesions into larger pus-filled bullae; and the associated findings of high fever and systemic malaise.^{2-4,6} Interesting clinical features seen in this case include the presence of clear bullae arranged in an annular configuration and the marked inflammatory oedema of the patient's lower limb unilaterally, mimicking an underlying deep vein thrombosis. Unusual manifestations that have been reported include mucous membrane erosions and nail bed involvement.^{2,10}

The skin biopsy resembled that of pustular psoriasis, with collections of neutrophils within the spongiotic epidermis and subcorneal layers. There was remarkable papillary oedema, correlating with the presence of inflammatory oedema clinically. Of note was the absence of parakeratosis and psoriasiform hyperplasia, which are more characteristic of pustular psoriasis. The absence of eosinophils was a useful distinguishing feature to exclude acute generalised exanthematous pustulosis.

The main urgency for the early recognition of IH is to anticipate and treat the associated systemic complications that can impact maternal and fetal well-being. These include significant systemic symptoms such as high fever, chills, nausea, vomiting, diarrhoea, seizures and malaise,^{2,3,6} as well as laboratory abnormalities such as leukocytosis, raised ESR, hypoalbuminaemia and iron deficiency anaemia,³ which were found in our case. Low levels of maternal serum calcium and phosphate have been reported as well.^{2,3,6} In addition, IH has been known to be triggered by hypoparathyroidism and after thyroidectomy.⁶

More importantly, IH has been associated with increased fetal morbidity, with reported complications such as stillbirth and placental insufficiency.^{2,3,6} Our case was associated with the premature rupture of membranes that required emergency operative delivery. In addition, the low birth weight of the baby is suggestive of underlying placental insufficiency with intrauterine growth retardation.

Apart from supportive therapy such as fluid and electrolyte replacement, systemic corticosteroids are the mainstay of

treatment.^{2,3,6,9} This is because there are limited drugs available in pregnancy to control this inflammatory condition, which is associated with many systemic complications. However, as evident in this case, adjuvant treatment with other drugs is indicated in poorly controlled disease or when the risks of high-dose corticosteroids are unacceptable. Other systemic treatments that have been used either as single agents or in combination with oral corticosteroids include oral psoralen and ultraviolet A (PUVA),⁶ systemic retinoids^{3,4,11} and cyclosporine.^{4,12-14} Of these, prednisolone and cyclosporine are safer alternatives in pregnancy as they are classified as category "C" in the United States Food and Drug Administration pregnancy safety index. It is important to note that both oral psoralens and retinoids are not approved for use during pregnancy, although retinoid teratogenicity does not occur in the last trimester. Breier-Maly et al³ reported a case of IH treated with oral corticosteroids during pregnancy, followed by retinoid-PUVA combination therapy after delivery, resulting in complete remission after 6 weeks.³

Although IH has been known to subside spontaneously after the delivery of the baby, this patient showed progressive clinical deterioration with persistence of a high fever, extension of her rash and associated inflammatory oedema, which necessitated active treatment. In our case, low-dose methotrexate was given after a careful discussion of the benefits and side effects of various treatment options with the patient. Methotrexate was chosen based on its proven efficacy in pustular psoriasis, short half-life, good safety profile and low cost. There has only been one other reported case in the literature of IH occurring in the puerperium that was treated with methotrexate and corticosteroids.⁶ Outpatient PUVA phototherapy was not suitable due to our patient's recent operation and severe limb oedema which limited her mobility. The long half-life of retinoid drugs such as acitretin^{15,16} was not ideal for our patient, who was keen on future pregnancies. Although our patient had no intention of breastfeeding her newborn even before her development of IH, a primary concern was the use of methotrexate in nursing mothers. As methotrexate has a short half-life of approximately 3 to 10 hours,¹⁷ our patient would theoretically have been able to start breastfeeding with minimal risk to the newborn 50 hours after her last dose of methotrexate. It is important to remember that methotrexate is contraindicated in pregnancy as it is an abortifacient. While the patient's subsequent clinical improvement may be attributed to a delayed response to the corticosteroids, the dramatic effect observed after starting low-dose methotrexate suggests that the latter drug was largely responsible for this improvement.

The successful use of this combination therapy suggests that methotrexate may be a suitable alternative or second-

line agent in the treatment of IH, especially in postpartum cases that are not responsive to systemic corticosteroids alone.

REFERENCES

1. Sauer GC, Geha BJ. Impetigo herpetiformis. *Arch Dermatol* 1961;83:173-80.
2. Henson TH, Tuli M, Bushore D, Talanin NY. Recurrent pustular rash in a pregnant woman. *Arch Dermatol* 2000;136:1055-60.
3. Breier-Maly J, Ortel B, Breir F, Schmidt JB, Honigsmann H. Generalized pustular psoriasis of pregnancy. *Dermatology* 1999;198:61-4.
4. Chang SE, Kim HH, Choi JH, Sung KJ, Moon KC, Koh JK. Impetigo herpetiformis followed by generalized pustular psoriasis: more evidence of same disease entity. *Int J Dermatol* 2003;42:754-5.
5. Lotem M, Katzenelson V, Rotem A, Hod M, Sandbank M. Impetigo herpetiformis: a variant of pustular psoriasis or a separate entity? *J Am Acad Dermatol* 1989;20:338-41.
6. Katsambas A, Stavropoulos PG, Katsiboulas V, Kostakis P, Panayiotopoulos A, Christofidou E, et al. Impetigo herpetiformis during the puerperium. *Dermatology* 1999;198:400-2.
7. Pierard GE, Pierard-Franchimont C, de la Brassinne M. Impetigo herpetiformis and pustular psoriasis during pregnancy. *Am J Dermatopathol* 1983;5:215-20.
8. Beveridge GW, Harkness RA, Livingstone JR. Impetigo herpetiformis in two successive pregnancies. *Br J Dermatol* 1966;78:106-12.
9. Wolf Y, Groutz A, Wilman I, Luxman D, David MP. Impetigo herpetiformis during pregnancy: case report and review of literature. *Acta Obstet Gynaecol Scand* 1995;74:229-32.
10. Winton GB, Lewis CW. Dermatoses of pregnancy. *J Am Acad Dermatol* 1982;6:977-98.
11. Gimenez Garcia R, Gimenez Garcia MC, Llorente de la Fuente A. Impetigo herpetiformis: response to steroids and etretinate. *Int J Dermatol* 1989;28:551-2.
12. Tada J, Fukushima S, Fujiwara Y, Akagi Y, Kodama H, Nohara N. Two sisters with impetigo herpetiformis. *Clin Exp Dermatol* 1989;14:82-4.
13. Imai N, Watanabe R, Fujiwara H, Ito M, Nakamura H. Successful treatment of impetigo herpetiformis with oral cyclosporin during pregnancy. *Arch Dermatol* 2002;138:128-9.
14. Finch TM, Tan CY. Pustular psoriasis exacerbated by pregnancy and controlled by cyclosporin A. *Br J Dermatol* 2000;142:582-4.
15. Larsen FG, Jakobsen P, Larsen CG, Kragballe K, Nielsen-Kudsk F. Pharmacokinetics of etretin and etretinate during long-term treatment of psoriasis patients. *Pharmacol Toxicol* 1988;62:159-65.
16. Rollman O, Vahlquist A. Retinoid concentrations in skin, serum and adipose tissue of patients treated with etretinate. *Br J Dermatol* 1983;109:439-47.
17. Roenigk HH Jr, Auerbach R, Maibach HI, Weinstein GD. Methotrexate in psoriasis: revised guidelines. *J Am Acad Dermatol* 1988;19:145-56.