

## Delayed Hypersensitivity Reaction After Intravenous Glucagon Administered for a Barium Enema: A Case Report

Ching Yin Neoh,<sup>1</sup>MBBS, MRCP, M Med (Int Med), Audrey WH Tan,<sup>1</sup>MBBS, MRCP, M Med (Int Med), Yung Hian Leow,<sup>1</sup>MBBS, M Med (Int Med), FAMS

### Abstract

**Introduction:** Few reports have documented allergic hypersensitivity reactions after barium gastrointestinal studies. Of these, the barium suspension, its additives or intravenous glucagon given for bowel relaxation has been implicated as possible allergens. We report a patient with delayed hypersensitivity reaction after barium enema and discuss the reasons supporting glucagon as the possible allergen. **Clinical Picture:** A 74-year-old Chinese woman presented with pruritic rashes, 1 day after a barium enema. Intravenous glucagon (GlucaGen®, Novo Nordisk, Denmark) was administered during the barium enema. Physical examination revealed palpable purpuric rashes on the legs with erythematous papules and plaques on the arms and trunk. Skin biopsy demonstrated superficial perivascular infiltrates of lymphocytes and eosinophils, consistent with a drug eruption. **Treatment and Outcome:** The rashes resolved with antihistamines and topical corticosteroids. **Conclusion:** This report highlights the potential of glucagon to cause hypersensitivity reactions. Awareness of this entity is important for the prevention and recognition of complications during barium gastrointestinal studies.

Ann Acad Med Singapore 2006;35:279-81

**Key words:** Gastrointestinal, Hypersensitivity, Parasympatholytics, Radiology

### Case Report

A 74-year-old Chinese woman presented with a 1-week history of an itchy rash on the trunk and legs. A barium enema was performed a day before the rash started. This was to investigate an incidental finding of a positive faecal occult blood test. Intravenous glucagon (GlucaGen®, Novo Nordisk, Denmark) 0.5 mg had been given as an intestinal muscle relaxant during the procedure. She was otherwise well, with no other symptoms of note.

The patient's other medications included naproxen sodium (Synflex®, Stevens Chem Industries, New Zealand), rofecoxib (Vioxx®, Merck Sharp & Dohme, New Jersey, United States of America), quinine sulphate (Beacons Pharmaceuticals, Singapore) and omeprazole (Omesec®, CCM Pharma, Malaysia). The first 3 medications were prescribed for joint pain while the last was for gastritis, all were started more than 1 month prior to onset of the current rash. She had previously taken rofecoxib without problems. Her other medical history included treated tuberculosis, a right knee replacement and hysterectomy for cervical intraepithelial neoplasia. This was her first exposure to intravenous glucagon. She did not have any prior drug allergy.

Physical findings showed palpable purpuric rash on the legs (Fig. 1) with erythematous papules and plaques on the arms and trunk. She was otherwise well with no systemic involvement.

A biopsy of the purpuric rashes showed superficial perivascular infiltrates of lymphocytes and eosinophils with extravasation of erythrocytes around the superficial vessels (Figs. 2a & 2b). The presence of eosinophils is compatible with a drug eruption. Direct immunofluorescence demonstrated deposits of C3 along the walls of the dermal blood vessels, consistent with vasculitis. Anti-nuclear antibody (ANA) was positive at 1 in 640. Anti-nuclear cytoplasmic antibody (p-ANCA) was also positive. There was mild transient transaminitis, which resolved spontaneously within 2 weeks.

She was diagnosed with allergic hypersensitivity reaction secondary to glucagon. The skin lesions resolved in 1 week with symptomatic treatment. She remained well 1 year later with no recurrence of rashes. ANA and p-ANCA was negative on repeat testing 1 year later.

### Discussion

Hypersensitivity reactions after barium studies are

<sup>1</sup> National Skin Centre, Singapore

Address for Reprints: Dr Neoh Ching Yin, National Skin Centre, 1 Mandalay Road, Singapore 308205.

Email: cyneoh@nsc.gov.sg

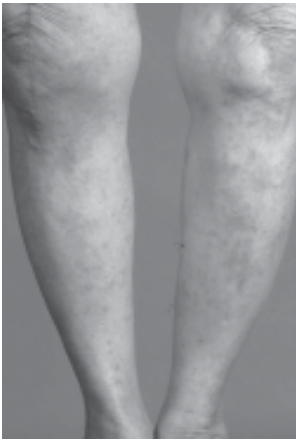

Fig. 1.

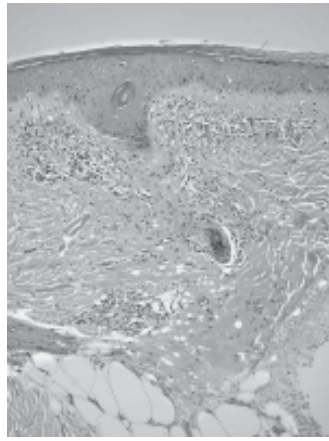


Fig. 2a.

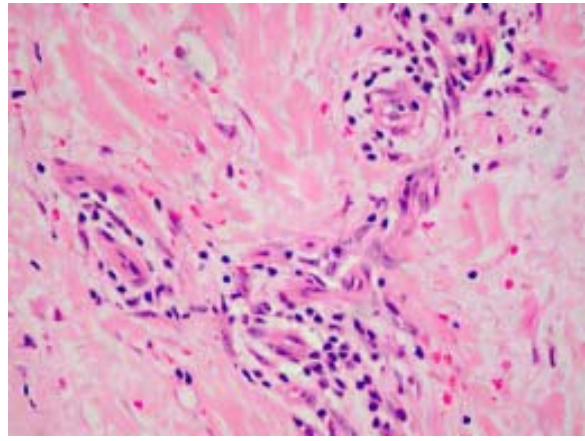


Fig. 2b.

Fig. 1. Palpable purpuric rashes on the lower limbs.

Fig. 2a. Superficial perivascular inflammatory infiltrate in the dermis (haematoxylin and eosin original magnification x20).

Fig. 2b. Perivascular infiltrates of lymphocytes and eosinophils with red cell extravasation around the superficial blood vessels (haematoxylin and eosin original magnification x40).

extremely uncommon with limited reports documenting adverse reactions. Of these, the barium suspension,<sup>1-3</sup> its additives<sup>4,5</sup> and intravenous glucagon given for bowel relaxation<sup>6-8</sup> have been incriminated as allergens. In our patient, the reasons to support glucagon as the culprit allergen are:

- 1) The delayed nature of the hypersensitivity reaction. Only glucagon has been reported to result in delayed hypersensitivity reactions. The other allergens are associated with immediate hypersensitivity reactions.
- 2) The inert nature of pure barium, making it non-antigenic and less likely to cause an allergy.
- 3) The absence of methylparaben and carboxymethylcellulose in the barium suspension used (EZEM<sup>®</sup>, E-Z-EM Inc., Westbury, New York, United States of America).

These are the only 2 additives reported to cause allergic reactions to date.<sup>4,5</sup>

Arguably, only a drug rechallenge can prove a direct causal relationship between glucagon and her rash. This is ideal but not necessarily practical as patients may not agree to undertake the risks involved in a drug rechallenge.

Of the handful of patients reported to have glucagon hypersensitivity, 2 patients had periorbital oedema with respiratory distress,<sup>6</sup> 1 had dizziness and shortness of breath<sup>7</sup> and another 2 had diffuse urticaria.<sup>6</sup> The last patient developed erythema multiforme 48 hours after intravenous glucagon was administered during a double contrast upper gastrointestinal examination.<sup>8</sup> None had prior exposure to glucagon. Parenteral administration of glucagon for bowel

distention has become common practice for double-contrast gastrointestinal radiology.<sup>9</sup> Glucagon is a naturally occurring polypeptide of 29 amino acids, currently synthesised in special non-pathogenic *Escherichia coli* genetically altered by the addition of the glucagon gene. Although glucagon is only contraindicated in patients with pheochromocytomas, glucagonomas and insulinomas,<sup>6</sup> these reports show that it may not be as innocuous and benign.

The significance of glucagon in hypersensitivity reactions after barium studies has been debated upon. As glucagon was not consistently used in patients reported to have allergic reactions after barium enemas, some felt that it was not the culprit allergen.<sup>1,2</sup> However, others have argued that barium, being inert, is not absorbed by colonic mucosa and is incapable of triggering a hypersensitivity reaction.<sup>2,4</sup> Among the numerous additives within barium suspensions, only methylparaben and carboxymethylcellulose have been implicated to cause allergic reactions.<sup>4,5</sup> Both additives were absent in the barium suspension that was used for our patient.

The delayed onset of the rash in our patient supports a delayed hypersensitivity reaction. However, we cannot exclude a non-immunologic mechanism underlying her reaction, as she has no prior glucagon exposure. The clinical history and findings of our patient met 3 out of the 5 criteria proposed by the American College of Rheumatology for the diagnosis of hypersensitivity vasculitis,<sup>10</sup> namely age older than 16 years, the use of an offending drug in temporal relation to the symptoms and the presence of palpable purpura. The other 2 criteria are the presence of a maculopapular rash and neutrophils around an arteriole or venule on skin biopsy. The presence of 3 or more of these criteria had a sensitivity and specificity for the diagnosis of hypersensitivity vasculitis of 71% and 84%, respectively.<sup>10</sup>

Besides glucagon, hyoscine butylbromide (Buscopan®, Duopharma, Malaysia) 20 mg administered intravenously is a good antispasmodic alternative for barium gastrointestinal studies and has been widely used in various centres for many years.<sup>11,12</sup> Compared to glucagon, hyoscine butylbromide produced better distension of the rectosigmoid colon and cost less.<sup>11</sup> However, glucagon allowed a longer time of distension for examination and gave better visualisation of the stomach for upper gastrointestinal barium studies.<sup>12</sup> Reports of pirenzepine,<sup>13</sup> cimetropium bromide<sup>14</sup> and peppermint oil mixed with the barium solution,<sup>15,16</sup> being used to relieve colonic spasm during barium enema are also available.

However, the former 2 antimuscarinic agents are not licensed for use in Singapore. No adverse reactions with the use of these antispasmodics were encountered in these reports. Like glucagon, the use of hyoscine butylbromide has been associated with acute urticaria and angioneurotic oedema.<sup>17-19</sup> In addition, hyoscine butylbromide has been reported to cause temporary impairment of visual accommodation<sup>20</sup> and fixed drug eruptions.<sup>21</sup> A thorough drug history and evaluation should be undertaken if it is to be considered as an alternative antispasmodic in this patient for future barium investigations.

## Conclusion

Barium gastrointestinal studies serve as useful alternatives to more invasive procedures like colonoscopy or gastroscopy. Greater awareness of the possible adverse reactions after barium enema will lead to improved surveillance for and treatment of these adverse reactions.

## REFERENCES

1. Feczko PJ. Increased frequency of reactions to contrast materials during gastrointestinal studies. *Radiology* 1990;174:367-8.
2. Janower ML. Hypersensitivity reactions after barium studies of the upper and lower gastrointestinal tract. *Radiology* 1986;161:139-40.
3. Brenner JS, O'Neil J, Kaude JV. Hypersensitivity reaction during barium enema [letter]. *AJR Am J Roentgenol* 1990;154:199.
4. Schwartz EE, Glick SN, Foggs MB, Silverstein GS. Hypersensitivity reactions after barium enema examination. *AJR Am J Roentgenol* 1984;143:103-4.
5. Muroi N, Nishibori M, Fujii T, Yamagata M, Hosoi S, Nakaya N, et al. Anaphylaxis from the carboxymethylcellulose component of barium sulfate suspension. *N Engl J Med* 1997;337:1275-7.
6. Gelfand DW, Sowers JC, DePonte KA, Sumner TE, Ott DJ. Anaphylactic and allergic reactions during double-contrast studies: is glucagon or barium suspension the allergen? *AJR Am J Roentgenol* 1985;144:405-6.
7. Herskovitz PI, Sendovski U. Severe allergic reaction to intravenous injection of glucagon. *Radiology* 1997;202:879.
8. Edell SL. Erythema multiforme secondary to intravenous glucagon. *AJR Am J Roentgenol* 1980;134:385-6.
9. Bova JG, Jurdi RA, Bennett WF. Antispasmodic drugs to reduce discomfort and colonic spasm during barium enemas: comparison of oral hyoscyamine, i.v. glucagon, and no drug. *AJR Am J Roentgenol* 1993;161:965-8.
10. Calabrese LH, Michel BA, Bloch DA, Arend WP, Edworthy SM, Fauci AS, et al. The American College of Rheumatology 1990 criteria for the classification of hypersensitivity vasculitis. *Arthritis Rheum* 1990;33:1108.
11. Goei R, Nix M, Kessels AH, Ten Tusscher MP. Use of antispasmodic drugs in double-contrast barium enema: glucagon or buscopan? *Clin Radiol* 1995;50:553-7.
12. Heron CW, Lynn AH, Marshall JH, Mason RR. A comparison of paralyzing agents in double-contrast barium meal examination. *Clin Radiol* 1985;36:391-3.
13. Maraccini P, Braccini G, Marrucci A, Boraschi P, Bertellotti L, Testa R. Pirenzepine vs scopolamine methylbromide in double-contrast barium enema of the large bowel. *Abdom Imaging* 1996;21:304-8.
14. Golfieri G, Porta E, Imbimbo BP, Muzio F. Efficacy of cimetropium bromide as pre-medication for double-contrast barium enema. *Br J Radiol* 1988;61:1087-8.
15. Asao T, Kuwano H, Ide M, Hirayama I, Nakamura JI, Fujita KI, et al. Spasmolytic effect of peppermint oil in barium enema during double-contrast barium enema compared with buscopan. *Clin Radiol* 2003;58:301-5.
16. Sparks MJ, O'Sullivan P, Herrington AA, Morcos SK. Does peppermint oil relieve spasm during barium enema? *Br J Radiol* 1995;68:841-3.
17. Gonzalez MR, Sanchez FC, Prieto MP, Cuevas M, Cena Delgado M, Sanchez CM. Acute urticaria induced by hyoscine butylbromide. *Allergy* 2004;59:787-8.
18. Thomas AM, Kubie AM, Britt RP. Acute angioneurotic oedema following a barium meal. *Br J Radiol* 1986;59:1055-6.
19. Robinson AC, Teeling M. Angioneurotic oedema and urticaria induced by hyoscine butylbromide. *Postgrad Med J* 1982;58:316.
20. Sissons GR, McQueenie A, Mantle M. The ocular effects of Buscopan in radiological practice. *Br J Radiol* 1991;64:584-6.
21. Kanwar AJ, Bharija SC, Singh M, Belhaj MS. Ninety-eight fixed drug eruptions with provocation tests. *Dermatologica* 1988;177:274-9.