

An Unusual Cause of Pulmonary Haemorrhage in a Patient with Rheumatoid Arthritis

MS Koh,¹MBBS, MRCP (UK), PH Leng,²MBBS, ABIM, P Eng,¹FAMS, M Med (Int Med), FCCP, J Hwang,³FAMS, MBBS, FRCPA

Abstract

Introduction: Pulmonary haemorrhage is a rare presentation of strongyloides hyperinfection. **Clinical Picture:** A 69-year-old female patient with rheumatoid arthritis on methotrexate and prednisolone presented with severe community acquired pneumonia. Intravenous trimethoprim/sulfamethoxazole (bactrim) and high dose hydrocortisone for *Pneumocystis carinii* pneumonia were commenced. She developed pulmonary haemorrhage 2 weeks later and bronchoalveolar lavage cytology revealed helminthic larvae identified as strongyloides. **Treatment and Outcome:** Despite treatment with ivermectin and albendazole with rapid tailing down of hydrocortisone, she succumbed to her illness. **Conclusions:** Strongyloides hyperinfection should be considered in an immunocompromised patient on high dose corticosteroid presenting with pulmonary haemorrhage. Prognosis remains dismal as supported by our case report and current literature.

Ann Acad Med Singapore 2004;33:365-7

Key words: Haemoptysis, Immunocompromised host, Outcome, Strongyloides hyperinfection

Introduction

Strongyloides stercoralis is an intestinal nematode which causes a chronic but usually asymptomatic infection in humans. However, in immunocompromised patients, parasitic larvae can develop rapidly and re-invade the host. This leads to uncontrolled proliferation and dissemination of the larvae throughout the body, i.e. hyperinfection syndrome.

There are only a few case reports of disseminated strongyloidiasis causing pulmonary haemorrhage.¹⁻⁵ The prognosis of this condition is dismal with mortality exceeding 70%.⁶ A high index of suspicion is required for diagnosis. Early treatment of the infection and tapering of corticosteroids seem to confer better overall prognosis.⁶

Case Report

A 69-year-old lady was admitted for complaints of cough with yellowish sputum and breathlessness of 3 days' duration. She had no recent travel history. She had seropositive rheumatoid arthritis (RA) for 2 years and had been on methotrexate 15 mg per week and oral prednisolone

4 mg per day for 10 months prior to admission.

On admission, she was febrile and arterial blood gas showed Type 1 respiratory failure. Chest radiograph revealed bilateral alveolar infiltrates. She rapidly developed acute respiratory distress syndrome (ARDS) and required mechanical ventilation. Bronchoscopy revealed purulent secretions from multiple lobes of the lungs. Bronchoalveolar lavage (BAL) was obtained from the right middle lobe. Intravenous trimethoprim/sulfamethoxazole (bactrim) at the dose of 15 mg/kg/day of the trimethoprim component with high dose intravenous hydrocortisone 100 mg 6 hourly were commenced for presumptive *Pneumocystis carinii* pneumonia (PCP). Intravenous vancomycin, imipenam and erythromycin were also initiated. Xigris (recombinant human activated protein C) was started and methotrexate was discontinued.

Bronchoalveolar lavage confirmed the presence of *Pneumocystis carinii* via silver methamine staining method and legionella pneumophila type 1 was isolated on culture. She initially improved but required re-intubation due to nosocomial pneumonia a few days later. A repeat

¹ Department of Respiratory and Critical Care Medicine

³ Department of Pathology

Singapore General Hospital, Singapore

² Division of Respiratory Medicine, Department of Medicine

National University Hospital, Singapore

Address for Reprints: Dr Mariko Siyue Koh, Department of Respiratory and Critical Care Medicine, Singapore General Hospital, Outram Road, Singapore 169608.

Email: gm3ksy@sgh.com.sg

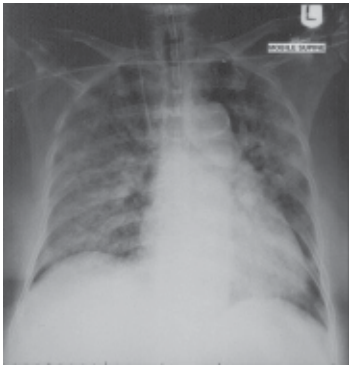


Fig. 1. Chest radiograph of the patient when she developed pulmonary haemorrhage. Bilateral alveolar infiltrates are seen.

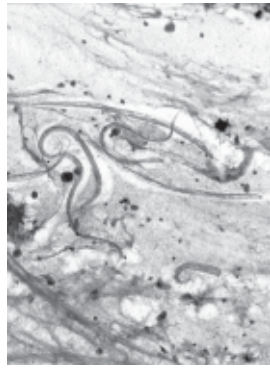


Fig. 2. Bronchoalveolar lavage showing many filariform larvae of strongyloides mixed with red blood cells and macrophages. (Pap stain x200)

bronchoscopy and BAL did not yield any new pathogens. Bactrim with high dose hydrocortisone were continued.

There were bloody endotracheal secretions seen necessitating a repeat bronchoscopy 2 weeks later (Fig. 1). Bronchoscopy yielded progressively bloodier BAL return from multiple lobes of both lungs. Coagulation profile was normal. Full blood count was as follows: white blood cell $13.05 \times 10^9/L$ (polymorphs 75%, eosinophils 1%, lymphocytes 5%, monocytes 8%, N myelocyte 11%), haemoglobin 7.9 g/dL, platelet $221 \times 10^9/L$. Haemoglobin level dropped by 2.0 g/dL from 10.0 g/dL on the previous day. Creatinine level remained stable at 82 $\mu\text{mol/L}$ and urine microscopy was unremarkable. Clinically her arthritis was quiescent.

Bronchoalveolar lavage sent for cytology revealed many helminthic larvae identified as strongyloides (Fig. 2). Ivermectin was commenced within 24 hours of the onset of pulmonary haemorrhage. Hydrocortisone dosage was rapidly tailed down over the next few days. Linear serpinginous, migratory erythematous rashes resembling “larva currens” were discovered over her lower abdomen and thighs. These are classically present over the perianal region but this was absent in our patient.

Microscopic examination of the stool revealed strongyloides over the next 4 days. The autoimmune panel including antinuclear antibody, antineutrophil cytoplasmic antibody, anti-Ro, anti-La, anti-ribosomal nuclear protein, rheumatoid factor and anti-basement membrane antibody was negative. Complement levels were normal. The rest of the BAL results did not yield any growth of pathogens. Stains for PCP and acid-fast bacilli were negative. Viral immunofluorescence and cultures including varicella zoster virus were negative. Human immunodeficiency virus (HIV) serology was negative.

She was given ivermectin for total of 3 days. Albendazole was added subsequently and continued for 2 weeks as the strongyloides larvae were still present in her stool after the course of ivermectin. Subsequent stool and tracheal aspirate did not reveal any larvae after 2 weeks of therapy. However, she developed recurrent nosocomial pneumonias and finally succumbed 8 weeks later from septic shock.

Discussion

The differential diagnosis of a patient who has pulmonary haemorrhage and a rheumatologic condition on immunosuppressants include diffuse alveolar haemorrhage (DAH) from flare of her RA, Wegener’s granulomatosis, microscopic polyangiitis, systemic lupus erythematosus (SLE), Goodpasture’s syndrome, Henoch-Schönlein purpura (HSP) and idiopathic haemosiderosis.⁶ Infective causes of DAH include mycoplasma infection, Legionnaire’s disease, varicella zoster pneumonitis, invasive aspergillosis and strongyloides stercoralis infection.^{1-5,7-9} In the absence of coagulopathies and the above causes, medications such as retinoic acid, propylthiouracil and phenytoin are considerations.⁶ In the absence of renal failure and nephritis, pulmonary-renal syndrome associated with Wegener’s granulomatosis, Goodpasture’s syndrome, SLE, HSP and microscopic polyangiitis was unlikely. Although rashes were present over the trunk and thighs, they were linear, migratory and serpinginous, unlike the vasculitic rashes characteristic of autoimmune diseases.

Although varicella pneumonia was a differential, it was unlikely based on negative immunofluorescence and culture from BAL. Clinically, the rash did not resemble that of varicella infection.

The occurrence of strongyloides causing pulmonary haemorrhage is rare.¹⁻⁵ In immunocompromised patients, strongyloides stercoralis which is usually found in the gastrointestinal system can invade the intestinal mucosa and disseminate haematogenously to the pulmonary capillaries. Massive proliferation of the larvae forms can occur in the presence of compromised cell-mediated immunity resulting in widespread dissemination, i.e. hyperinfection.

Strongyloides hyperinfection syndrome may present with ARDS, lung microabscesses, pulmonary haemorrhage and secondary bacterial infection as intestinal gram-negative bacilli “piggy-back” onto the larvae and are transported throughout the body.^{10,11} The risk of hyperinfection is greatest in patients with chronic lung diseases and impairment of cellular immunity. Peripheral blood eosinophilia is often absent, as in our patient, due to suppression of eosinophils by corticosteroids or associated bacterial infection.⁶

The prognosis for strongyloides hyperinfection is poor

with high relapse rate of 15%.¹² Despite proper treatment, mortality rate exceeds 70% in all patients with hyperinfection syndrome. The prognosis for those who present with pulmonary haemorrhage seem even more dismal.^{1-3,5} All patients reported died from massive pulmonary haemorrhage or pneumonia. The underlying co-morbidities of reported patients included SLE, T-cell lymphoma, asthmatic on high dose corticosteroids, HIV infection and 1 patient had no identified underlying medical condition. Based on our review of the literature, we found only 1 survivor who lived despite having pulmonary haemorrhage and strongyloides infection. This patient had acquired immune deficiency syndrome and PCP infection for which high dose glucocorticoids were probably responsible for the strongyloides hyperinfection.⁴

Delay in diagnosis and treatment, and continued immunosuppression were thought to further contribute to the poor outcome.¹² Although the diagnosis was established within 24 hours in our patient and appropriate treatment was commenced with rapid tailing down of corticosteroids, our patient succumbed eventually. Unfortunately, the presence of an immunocompromised state rendered her susceptible to recurrent infections.

In view of the continued presence of hyperinfection and presence of strongyloides larvae in the stools despite the completion of ivermectin, albendazole was added and continued for another 2 weeks. There are currently no guidelines for the treatment of strongyloides hyperinfection in the immunocompromised patients. Deaths occurring from disseminated disease with conventional therapy of 2 to 3 days have been reported before and therefore some authors recommend prolonged treatment in patients with hyperinfection.^{3,13,14} Combination therapy should be considered if there is no clinical response or relapse is evident, as was the case in our patient.¹⁴

In conclusion, a high index of suspicion is required to diagnose strongyloides infection in an immuno-

compromised patient. Pulmonary haemorrhage is a rare presentation and rapid diagnosis and treatment may confer a better prognosis. However, mortality exceeds 70% and it remains an extremely devastating infection.

REFERENCES

1. Setoyama M, Fukumaru S, Takasaki T, Yoshida H, Kanzaki T. SLE with death from acute massive pulmonary haemorrhage caused by disseminated strongyloidiasis. *Scand J Rheumatol* 1997;26:389-91.
2. Kinjo T, Tshako K, Nakazato I, Ito E, Sato Y, Koyanagi Y, Iwamasa T. Extensive intra-alveolar haemorrhage caused by disseminated strongyloidiasis. *Int J Parasitol* 1998;28:323-30.
3. Daya U, Jain M, Corgridge T. Pulmonary hyperinfection syndrome with strongyloides stercoralis. *Chest* 1999;116:425-6S.
4. Cohen L, Lefrak SS. Strongyloides hyperinfection syndrome secondary to treatment of pneumocystis carinii pneumonia. *Chest* 2001;120:346-7S.
5. Harcourt-Webster JN, Scaravilli F, Darwish AH. Strongyloides stercoralis hyperinfection in an HIV positive patient. *J Clin Pathol* 1991;44:346-8.
6. Schwarz MI, King TE, Cherniack RM. Principles of and approach to the patient with interstitial lung disease. In: Murray JF, Nadel JA, editors. *Textbook of Respiratory Medicine*. 3rd ed. Philadelphia, PA: WB Saunders, 2000:1649-70.
7. Kane JR, Shenep JL, Krance RA, Hurwitz CA. Diffuse alveolar haemorrhage associated with mycoplasma hominis respiratory tract infection in a bone marrow transplant recipient. *Chest* 1994;105:1891-2.
8. Kim EA, Lee KS, Primack SL, Yoon HK, Byun HS, Kim TS, et al. Viral pneumonias in adults: radiologic and pathologic findings. *Radiographics* 2002;22:S137-49.
9. Marruchella A, Franco C. Severe alveolar haemorrhage in legionella pneumonia. *Sarcoidosis Vasc Diffuse Lung Dis* 2003;20:77.
10. Thompson JR, Berger R. Fatal adult respiratory distress syndrome following successful treatment of pulmonary strongyloidiasis. *Chest* 1991;99:772-4.
11. Cook GA, Rodriguez H, Silva H. Adult respiratory distress secondary to strongyloidiasis. *Chest* 1987;92:115-6.
12. Woodring JH, Halfhill H, Reed JC. Pulmonary strongyloides: Clinical and imaging features. *AJR Am J Roentgenol* 1994;162:537-42.
13. Chu E, Whitlock WL, Dietrich RA. Pulmonary hyperinfection syndrome with strongyloides stercoralis. *Chest* 1990;97:1475-7.
14. Lessnau KD, Can S, Talavera W. Disseminated strongyloides stercoralis in human immunodeficiency virus-infected patients. Treatment failure and a review of the literature. *Chest* 1993;104:119-22.