

A New Method for the Removal of Safety Pins Ingested by Children

Zafer Türkyılmaz,^{1MD}, Ramazan Karabulut,^{1MD}, Kaan Sönmez,^{1MD}, Abdullah Can Basaklar,^{1MD}, Nuri Kale,^{1MD}

Abstract

Introduction: Foreign body ingestion is a common problem in children. Safety pin ingestion is common in Turkey. We describe a new method of removal for safety pins in our 2 cases. **Clinical Picture:** A 9-month-old girl and a 6-month-old boy had each ingested a safety pin. Abdominal X-rays detected the safety pins in their stomachs. At the end of 3 months, the foreign bodies still remained in their stomachs and laparotomy was indicated. **Treatment and Outcome:** This technique consists of a limited midline upper laparotomy with vertical incision. Without the utilisation of a gastrotomy, an orogastric tube was inserted into the stomach and the open end of the safety pin was pinned to the tube from outside the stomach. The orogastric tube was gently pulled out to remove the safety pin. **Conclusion:** This method provides shorter hospitalisation time and fewer complications.

Ann Acad Med Singapore 2007;36:206-7

Key words: Children, Safety pin ingestion

Introduction

Foreign body ingestion is a relatively common problem, with an estimated incidence of 120 per 1 million population, resulting in approximately 1500 deaths each year. Toddlers form the most vulnerable group. Swallowed objects may be true foreign bodies such as coins, plastic toys, bones, pins and disc batteries.^{1,2} The type of foreign body and its clinical presentation vary in people of different ages and culture and require special management.³

Currently, several methods are being used for the removal of different foreign bodies. We describe a new method for the removal of an open safety pin in the stomach. This approach is discussed in this study.

Case Report

A 9-month-old girl and a 6-month-old boy had each ingested a safety pin (Fig. 1). Abdominal X-rays detected the safety pins in the stomach. No pathological signs were found by physical examination. These patients were frequently examined by means of palpation and plain abdominal radiographs. By the end of 3 months, the foreign bodies still remained in the stomach and laparotomy was indicated.

Operative Technique

A midline laparotomy was performed under general anaesthesia. The open end of the safety pin in the stomach was passed through the hole on the end of orogastric tube, which is easily palpated from outside the stomach. Thereafter, the safety pin was locked and the orogastric tube was pulled out of the mouth with the safety pin, without the utilisation of a gastrotomy. Maximal care was given to the vertical position of the safety pin in relation to the orogastric tube (Figs. 2a and 2b).

Discussion

Ingested foreign bodies usually pass the intestinal tract without problems and perforation occurs in less than 1% of cases. In less than 2% of perforated cases, the stomach is involved. They are usually long, hard, sharp and indigestible foreign bodies such as toothpicks and safety pins.⁴ Prasad et al⁵ and Selivanov et al⁶ suggested that foreign bodies which passed into the stomach can be observed for the development of symptoms, since 80% of them passed through the gastrointestinal tract without any complications

Zuloaga et al⁷ also suggested a conservative approach for the treatment of foreign body ingestion. For objects lodged

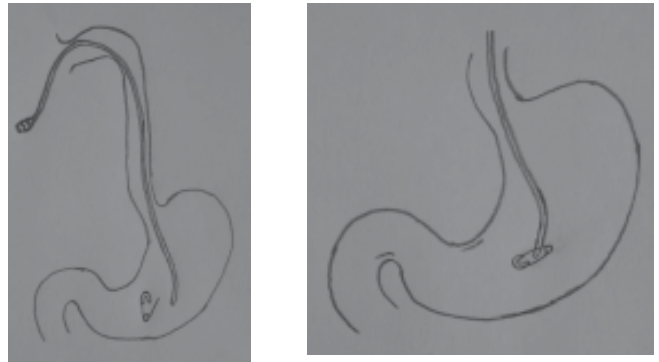
¹ Gazi University Faculty of Medicine, Department of Pediatric Surgery, Ankara, Turkey
Address for Correspondence: Dr Zafer Türkyılmaz, Kizilarpinari cad. No 31/10, 06300 Keçiören, Ankara, Turkey.
Email: zafertk@yahoo.com

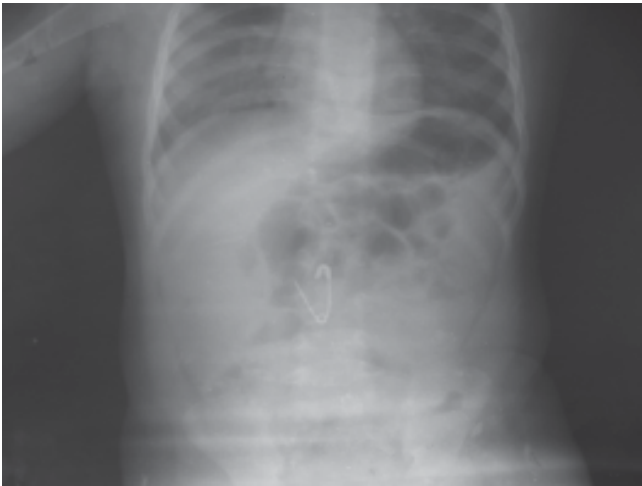

Fig. 1. Abdominal plain roentgenogram revealed an open end safety-pin, which was located in the upper abdomen.

in the oesophagus, endoscopic removal is indicated. For objects in the stomach, a 2-month waiting period is recommended; for objects located in the lower gastrointestinal tract, a 15-day wait before laparotomy is indicated. Most reports agree that observation until the patient becomes symptomatic is the best approach for the management of foreign body ingestion. In fact, James et al⁸ reported several cases in which foreign bodies had been in place for up to 3 years with no complications. We waited for 3 months because the patients did not have any clinical symptoms urging surgical intervention and with the expectation that the safety pin would be expelled.

The ingestion of safety pins is common in children in Turkey, because of the wide use of blue bead as a talisman.³ Blue bead is a blue glass bead of 1 cm in diameter. The blue bead is attached to the child's suit with a safety pin. In a series of 49 swallowed safety pins, 20 children passed the safety pins spontaneously, 14 required endoscopic removal and 15 underwent surgical intervention. None of these patients were symptomatic before operation.³ Morbidity rates were well below 1% with both (rigid and flexible) types of oesophagoscopy in the setting of foreign body removal,⁹ although the true perforation rate may be unknown because of non-reporting by some operators.⁹ In another study, 6% of complications occurred including 3 oesophageal tears.¹⁰ The overall rate of perforation from foreign bodies objects is estimated at <1%. However, when considering sharp objects alone, the incidence of perforation increases to 15% to 35%.¹¹ Endoscopic extraction of large, sharp foreign bodies often poses technical difficulties and risk of dangerous complications such as perforation, peritonitis and mediastinitis. In the case of a thin, pointed foreign body, retrieval can be performed by simply grasping its pointed end with a suitable snare or forceps and pulling it back to the tip of scope or within the biopsy channel.



Figs. 2a and 2b. Schematic representation of the new technique an orogastric tube was inserted into the stomach (2a) and the open end SP was pinned to the tube and removed without gastrotomy (2b).

When a foreign body with a cutting edge must be removed, a protector device is usually needed. Plastic end hood has been suggested.¹¹ We did not attempt the endoscopic removal because of the lack of sufficient equipment to extract the safety pin in a safe way.

In conclusion, frequently occurring safety pin ingestions in Turkey need a higher rate of laparotomy. This method provides a lower rate of contaminated extraction, shorter hospitalisation, a lower wound infection rate, as well as lower treatment costs in this group of patients.

REFERENCES

- Berggreen PJ, Harrison E, Sanowski RA, Ingebo K, Noland B, Zierer S. Techniques and complications of esophageal foreign body extraction in children and adults. *Gastrointest Endosc* 1993;39:626-30.
- Rajagopal A, Martin J, Matthai J. Ingested needles in a 3-month-old infant. *J Pediatr Surg* 2001;36:1450-1.
- Gun F, Salman T, Abbasoglu L, Celik R, Celik A. Safety-pin ingestion in children: a cultural fact. *Pediatr Surg Int* 2003;19:482-4.
- Steenvoorde P, Moues CM, Viersma JH. Gastric perforation due to the ingestion of a hollow toothpick: report of a case. *Surg Today* 2002;32:731-3.
- Prasad TS, Low Y, Tan CE, Jacobsen AS. Swallowed foreign bodies in children: report of four unusual cases. *Ann Acad Med Singapore* 2006;35:49-5.
- Selivanov V, Sheldon GF, Cello JP, Crass RA. Management of foreign body ingestion. *Ann Surg* 1984;199:187-91.
- Zuloaga J, Olivera J, Candia A, Arias V, de la Fuente A. Ingestion of foreign bodies in a prison population: surgical treatment. *Rev Esp Enferm Apar Dig* 1987;72:617-21.
- James AH, Allen-Mersh TG. Recognition and management of patients who repeatedly swallow foreign bodies. *J R Soc Med* 1982;75:107-10.
- Webb WA. Management of foreign bodies of the upper gastrointestinal tract. *Gastroenterology* 1988;94:204-16.
- Blaho KE, Merigian KS, Winbery SL, Park LJ, Cockrell M. Foreign body ingestions in the Emergency Department: case reports and review of treatment. *J Emerg Med* 1998;16:21-6.
- Bertoni G, Pacchione D, Sassatelli R, Ricci E, Mortilla MG, Gumina C. A new protector device for safe endoscopic removal of sharp gastroesophageal foreign bodies in infants. *J Pediatr Gastroenterol Nutr* 1993;16:393-6.