

## A Novel Mutation of the VMD2 Gene in a Chinese Family with Best Vitelliform Macular Dystrophy

Yang Li,<sup>1</sup>MD, Guanglu Wang,<sup>2</sup>MD, Bing Dong,<sup>1</sup>MS, Xiuying Sun,<sup>1</sup>MS, Matthew J Turner,<sup>3</sup>MSPH, Shin Kamaya,<sup>3</sup>BSE, Kang Zhang,<sup>3</sup>MD, PhD

### Abstract

**Introduction:** In this paper, we report a novel VMD2 gene mutation in a Chinese family with Best vitelliform macular dystrophy. **Materials and Methods:** Ophthalmologic examination and optical coherence tomography (OCT) were performed in 2 members of this family. Mutational screening was performed by single-strand conformation polymorphism (SSCP) and direct sequencing of PCR-amplified DNA fragments, corresponding to the 11 exons of the gene. **Results:** Sequence analysis identified a previously unreported C to G change, predicting a Phe-113-Leu substitution. Both the proband and his sister harboured this novel mutation. Each had bilateral vitelliform lesions. **Conclusions:** A novel mutation in the VMD2 gene (C427G) was found in Chinese patients with Best vitelliform macular dystrophy.

Ann Acad Med Singapore 2006;35:408-10

**Key words:** Best macular dystrophy, Bestrophin, Retinal pigment epithelium

### Introduction

Best vitelliform macular dystrophy is an autosomal dominant disorder characterised by an egg yolk-like appearance of the macula. The vitelliform “egg yolk” lesions result from abnormal accumulation of lipofuscin in the retinal pigment epithelium (RPE). Variable expression may be observed among affected family members, and the disease may present asymmetrically in a given patient. Clinical features vary in the different stages of disease. In the early stages, accumulation of lipofuscin-like material in the RPE is observed, but acuity remains excellent. Disorganisation of the RPE eventually affects the overlying photoreceptors and leads to vision loss.<sup>1</sup> Electro-oculography (EOG) is abnormal in affected individuals, even in the presence of a normal fundus.<sup>2</sup>

In 1992, VMD2 was mapped to the long arm (q13) of chromosome 11,<sup>3</sup> and the VMD2 gene has been identified by positional cloning as the gene causing Best vitelliform macular dystrophy.<sup>4,5</sup> The gene contains 11 exons and encodes a 585-amino-acid protein known as bestrophin, which is selectively expressed in the retinal pigment epithelium (RPE) and has sequence homology with the RFP protein family. Marmorstein et al<sup>6</sup> demonstrated that

bestrophin is a plasma membrane protein localised to the basolateral surface of RPE cells. Recently, Sun et al<sup>7</sup> demonstrated that bestrophin belongs to a new chloride channel family.

Since VMD2 was cloned, 79 mutations associated with Best vitelliform macular dystrophy have been reported.<sup>4,5,8-10</sup> In this study, we present a Chinese family with Best vitelliform macular dystrophy and describe a novel mutation in the VMD2 gene.

### Materials and Methods

This study was granted approval from the Beijing Tongren Hospital Joint Committee on Clinical Investigation. Informed consent was obtained from all individuals. Two individuals at risk for Best vitelliform macular dystrophy in a small Chinese family participated in this study (Fig. 1).

### Clinical Examination

Both individuals underwent clinical examination including best-corrected visual acuity measurement, slit-lamp examination, dilated fundoscopic examination and optical coherence tomography (OCT) examination (Professional series PT 770, Humphrey Instruments, San Leandro, CA, USA).

<sup>1</sup> Beijing Institute of Ophthalmology, China

<sup>2</sup> Department of Ophthalmology, Beijing Tongren Hospital, Capital University of Medical Science, China

<sup>3</sup> Department of Ophthalmology and Visual Sciences, John A. Moran Eye Center, University of Utah Health Sciences Center, Utah, USA

Address for Reprints: Dr Kang Zhang, Eccles Institute of Human Genetics, 15 North 2030 East, Bldg 533, University of Utah, Salt Lake City, UT 84132, USA. Email: yangli64@hotmail.com (YL) and kang.zhang@hmbg.utah.edu (KZ)

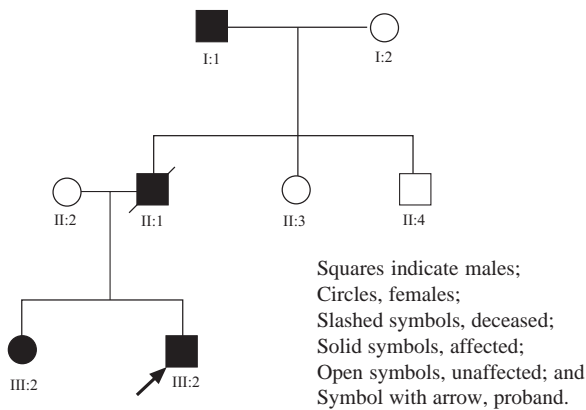


Fig. 1. Pedigree of the family with Best Vitelliform macular dystrophy. Individuals are identified by generation.

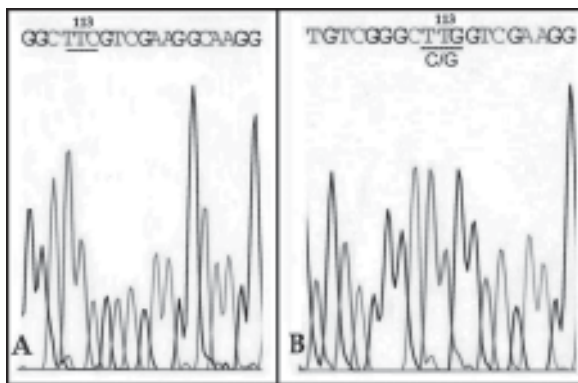


Fig. 3. Direct sequencing analysis of the VMD2 gene of patients in the family with the F113L mutation; (A) wild-type allele (B) mutant allele.

### Molecular Studies

Blood samples were obtained by venipuncture, and genomic DNA was extracted using standard methods. All 11 exons of the VMD2 gene were amplified by polymerase chain reaction (PCR) using primers as reported previously.<sup>4,5</sup> Mutation screening was carried out by the single-strand conformation polymorphism (SSCP) technique. Amplified DNA was mixed with an equal volume of formamide buffer (95% formamide, 10 Mm EDTA, 0.1% bromophenol blue, 0.1% xylene cyanol). Denatured samples underwent electrophoresis on a 14% non-denaturing polyacrylamide gel (acrylamide:bisacrylamide = 49:1) for 12 to 16 hours at 300 v at 4°C. After electrophoresis, gels were silver-stained and analysed.<sup>11</sup> Individual exons that showed aberrant band shifts were sequenced in 2 directions by ABI Prisms 310 Genetic Analyzer. The exon 4 heterozygous PCR product was subcloned into the pGEM-T Easy vector (Promega) prior to sequencing of the mutant and wild-type alleles, using internal gene-specific primers.

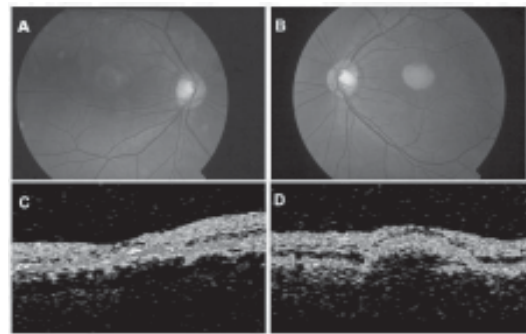


Fig. 2. Proband. Ophthalmoscopic appearance of the right eye (A) with faded vitelliform lesions, and left eye (B) with a typical vitelliform lesion. OCT images through the fovea show a highly reflective thickened layer at the level of the RPE and choriocapillaris of both eyes (C and D), and well-circumscribed elevation of the retinal pigment epithelium in the left eye (D).

## Results

### Clinical Characterisation

The proband and his sister, who were at risk for Best vitelliform macular dystrophy, were examined. The proband was a 28-year-old Chinese male who presented with vague complaints of metamorphopsia. His best-corrected visual acuity was 20/200 OD, 20/50 OS. Dilated fundoscopic examination demonstrated a faded vitelliform macular lesion associated with RPE atrophy in the right eye; a typical vitelliform-like macular lesion was observed in the left eye (Figs. 2A and 2B). OCT images acquired through the yellow macular lesions showed a highly reflective thickened layer at the level of the RPE and choriocapillaris in both eyes of the proband. There was a well-circumscribed elevation of the RPE in the left eye (Figs. 2C and 2D). The proband's sibling demonstrated vitelliform-like lesions in both macular regions; there was no associated visual deficit. Her best-corrected visual acuity was 20/20 OU.

### Detection of Mutation

SSCP analysis of the VMD2 gene coding region in the 2 affected patients revealed a shift band on exon 4. Then, sequence analysis of exon 4 revealed a C-to-G change on 427, predicting a Phe-113-Leu substitution (Fig. 3). This sequence change segregated with the disease phenotype and was not observed in 100 control chromosomes.

### Discussion

In this study, we have identified a novel mutation in the VMD2 gene, F113L in a Chinese family affected with Best vitelliform macular dystrophy. Although the F113L mutation in exon 4 of VMD2 gene does not occur at highly conserved amino acid residues, the VMD2 gene F113L is expected to be pathogenic. First, the mutation altered the predicted amino acid sequence of the VMD2 gene. Second, the mutation was cosegregated with the affected patients in this family and was not found in 100 normal control

individuals.

To date, 79 different mutations have been identified in Best Macular dystrophy patients. These are summarised at the VMD2 mutation database ([www.uni-wuerzburg.de/humangenetics/vmd2.html](http://www.uni-wuerzburg.de/humangenetics/vmd2.html)). Of these, 75 are missense mutations resulting in substitutions at 56 different amino acids. The mutations mainly cluster in or near exons 2, 4, 6 and 8, which are the regions of predicted transmembrane domains. This suggests these regions may have an important functional role.

Bestrophin, which has an approximate mass of 68 kDa, shares a homology with the *C. elegans* RFP gene family, named for the presence of a conserved arginine (R), phenylalanine (F), proline (P), amino acid sequence motif.<sup>4,5</sup> Immunocytochemical staining of macaque and porcine eyes indicated that bestrophin is localised at the basolateral plasma membrane of the RPE.<sup>6</sup> Sun et al<sup>7</sup> recently provided evidence that bestrophin and other RFP family members represent a new class of chloride channels, indicating a direct role for bestrophin in generating the light peak. Marmorstein et al<sup>12</sup> have demonstrated that bestrophin is in the signal transduction pathway that modulates the light peak of the electro-oculogram, and that it is regulated by phosphorylation.

In summary, we have identified a novel VMD2 sequence variation in a Chinese family with Best vitelliform macular dystrophy. The diversity of mutations in the VMD2 gene that can result in a similar clinical phenotype attests to this gene's central role in maintaining the function of the RPE. Further characterisation of the VMD2 gene mutations in the development of Best macular dystrophy may yield insight into the pathogenesis of these disorders, and possibly lead to the development of new treatment strategies.

#### REFERENCES

1. Godel V, Chaine G, Regenbogen L, Coscas G. Best's vitelliform macular dystrophy. *Acta Ophthalmol Suppl* 1986;175:1-31.
2. Cross HE, Bard L. Electro-oculography in Best's macular dystrophy. *Am J Ophthalmol* 1974;77:46-50.
3. Stone EM, Nichols BE, Streb LM, Kimura AE, Sheffield VC. Genetic linkage of vitelliform macular degeneration (Best's disease) to chromosome 11q13. *Nat Genet* 1992;1:246-50.
4. Petrukhin K, Koisti MJ, Bakall B, Li W, Xie G, Marknell T, et al. Identification of the gene responsible for Best macular dystrophy. *Nat Genet* 1998;19:241-7.
5. Marquardt A, Stohr H, Passmore LA, Kramer F, Rivera A, Weber H. Mutations in a novel gene, VMD2, encoding a protein of unknown properties cause juvenile-onset vitelliform macular dystrophy (Best's disease). *Hum Mol Genet* 1998;7:1517-25.
6. Marmorstein AD, Marmorstein LY, Rayborn M, Wang X, Hollyfield JG, Petrukhin K. Bestrophin, the product of the Best vitelliform macular dystrophy gene (VMD2), localizes to the basolateral plasma membrane of the retinal pigment epithelium. *Proc Natl Acad Sci USA* 2000;97:12758-63.
7. Sun H, Tsunenari T, Yau KW, Nathans J. The vitelliform macular dystrophy protein defines a new family of chloride channels. *Proc Natl Acad Sci USA* 2002;99:4008-13.
8. Caldwell GM, Kakuk LE, Griesinger IB, Simpson SA, Nowak NJ, Small KW, et al. Bestrophin gene mutations in patients with Best vitelliform macular dystrophy. *Genomics* 1999;58:98-101.
9. Lotery AJ, Munier FL, Fishman GA, Weleber RG, Jacobson SG, Affatigato LM, et al. Allelic variation in the VMD2 gene in best disease and age-related macular degeneration. *Invest Ophthalmol Vis Sci* 2000;41:1291-6.
10. Yanagi Y, Sekine H, Mori M. Identification of a novel VMD2 mutation in Japanese patients with Best disease. *Ophthalmic Genet* 2002;23:129-33.
11. Wang Q, Shen J, Splawski I, Atkinson D, Li Z, Robinson JL, et al. SCN5A mutations associated with an inherited cardiac arrhythmia, long QT syndrome. *Cell* 1995;80:805-11.
12. Marmorstein LY, McLaughlin PJ, Stanton JB, Yan L, Crabb JW, Marmorstein AD. Bestrophin interacts physically and functionally with protein phosphatase 2A. *J Biol Chem* 2002;277:30591-7.