

## Multifocal Skeletal Tuberculosis Presenting as Multiple Bone Cysts

Dear Editor,

Multifocal skeletal tuberculosis is rare, and accounts for 10% of all cases of osteoarticular tuberculosis.<sup>1</sup> We report one such case for its unusual clinicoradiological picture, which was more compatible with a benign bone tumour rather than an infectious disease.

A 22-year-old male presented with pain in the left ankle for about 1 month, with no history of trauma, fever, weight loss or loss of appetite. There was no evidence of any systemic illness. The ankle was normal on inspection, while deep palpation revealed tenderness just behind the medial malleolus.

The haemogram of the patient was normal, with an erythrocyte sedimentation rate of 5 mm in the first hour. A radiograph of the ankle showed a well-delineated lytic area in the posteromedial part of the body of talus (Fig. 1). A diagnosis of a bone cyst was considered, the possibilities being inclusion cyst, simple bone cyst, aneurysmal bone cyst or a giant cell tumour. A computed tomography (CT) scan of both the ankles incidentally showed a similar lesion in the contralateral calcaneum. A skeletal survey showed another lesion in the distal metaphysis of the right radius. All the 3 lesions showed reactive sclerosis with no evidence of sequestration or articular involvement. A provisional diagnosis of multifocal giant cell tumour or multiple bone cysts was made.

A biopsy was obtained from the distal end of right radius. The material appeared caseous, and the wound showed evidence of a serous discharge on follow-up. The histopathology report showed granulomata with central caseation. Staining and culture were both negative and polymerase chain reaction for tuberculosis was positive. The tuberculin test showed an induration of 18 mm. A chest X-ray and ultrasonography of the abdomen revealed no abnormality, and ELISA for human immunodeficiency virus was negative. An antitubercular treatment with 4 drugs was administered for a period of 1 year. At the final follow-up of 18 months, the patient was free of symptoms, though there was little change in the radiological picture except increased sclerosis at the margin of the lesion.

The outcome of tubercular infection of an individual depends on the immune status of the individual and the bacillary load.<sup>2</sup> Multifocal tuberculosis, brought about by a disseminated haematogenous impregnation, is found almost exclusively in those with a compromised immune

status.<sup>1,3,4</sup> On the other hand, those with a good immune status may show spontaneous resolution.

Osseous tuberculosis is known to have a higher incidence in male children, and our patient too was a young male. However in this patient, it was interesting that 2 of the hallmarks of multifocal tuberculosis – visceral lesions (pulmonary involvement being the commonest<sup>4</sup>) and constitutional features<sup>1</sup> – were absent. This may reflect a change in the immune status of the patient from poor immunity (when the hematogenous bacillary impregnation(s) occurred) to good immunity (when the patient presented). Two of the 3 lesions at the time of presentation were asymptomatic. It is probable that these lesions were already on their way to spontaneous healing brought about by a change in immunity of the patient. The reactive sclerosis found around the lesions also supports this explanation, as active tubercular lesions are usually without any marginal sclerosis.<sup>4</sup>

The sites involved in this case were all unusual. Tarsal bones account for less than 1% of all cases of osteoarticular tuberculosis.<sup>4</sup> This patient had tuberculosis of the talus, without the involvement of the ankle or subtalar joints, which is very rare.<sup>5</sup> Radius is also considered one of the unusual sites of involvement by tuberculosis.<sup>2</sup>

Due to these reasons, we were misled to believe that a tumour or cyst was the likely diagnosis. Multifocal skeletal tuberculosis must be considered as a differential diagnosis in a case with multiple bone cysts. Multidrug antitubercular therapy alone usually leads to complete resolution, provided the diagnosis is prompt, which is possible only if a high index of suspicion is maintained.

### REFERENCES

1. Tuli SM. Tuberculous osteomyelitis. In: Tuli SM, editor. Tuberculosis of the Skeletal System. 2nd ed. New Delhi: Jaypee Brothers, 2000.
2. Goldblatt M, Cremin BJ. Osteo-articular tuberculosis: its presentation in coloured races. *Clin Radiol* 1978;29:669-77.
3. Dhammi IK, Jain AK, Singh S, Aggarwal A, Kumar S. Multifocal skeletal tuberculosis in children: a retrospective study of 18 cases. *Scand J Infect Dis* 2003;35:797-9.
4. Morris BS, Varma R, Garg A, Awasthi M, Maheshwari M. Multifocal musculoskeletal tuberculosis in children: appearances on computed tomography. *Skeletal Radiol* 2002;31:1-8.
5. Anand A, Sood LK. Isolated tuberculosis of talus without ankle and subtalar joint involvement. *Med J Malaysia* 2002;57:371-3.

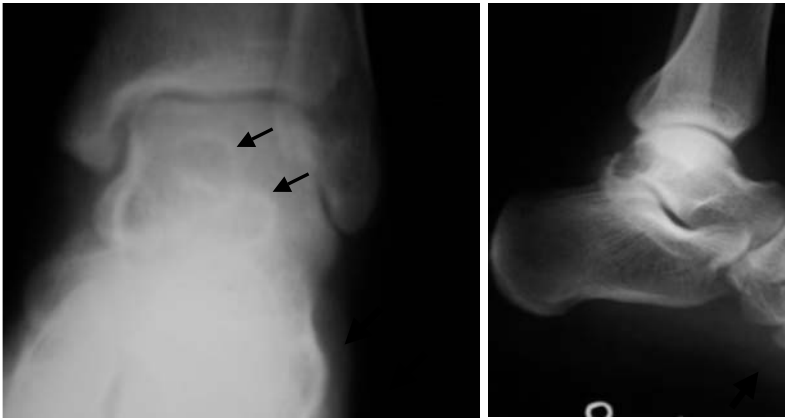

Fig. 1a. Radiograph showing lytic area in the talus (arrows) with sclerotic margins.

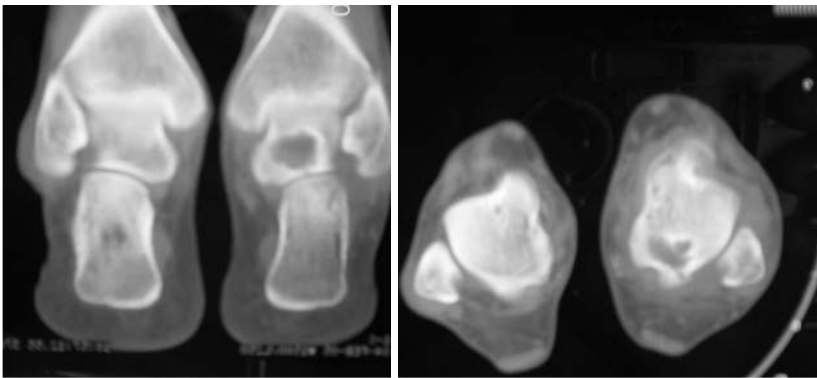


Fig. 1b. CT scan of both ankles showing lytic lesions in the left talus and right calcaneum without any sequestra/soft tissue shadows.

Akshay Tiwari,<sup>1</sup>*MS*, Alok Sud,<sup>1</sup>*MS*, Sameer Mehta,<sup>1</sup>*MS*,  
RK Kanojia,<sup>1</sup>*MS*, Sudhir K Kapoor,<sup>1</sup>*MS*

<sup>1</sup> Department of Orthopaedics, Lady Hardinge Medical College and  
Associated Hospitals, New Delhi, India

Address for Correspondence: Dr Akshay Tiwari, D-I/80, Bharti Nagar, New  
Delhi, India 110003.

Email: akshay\_t\_2000@yahoo.com