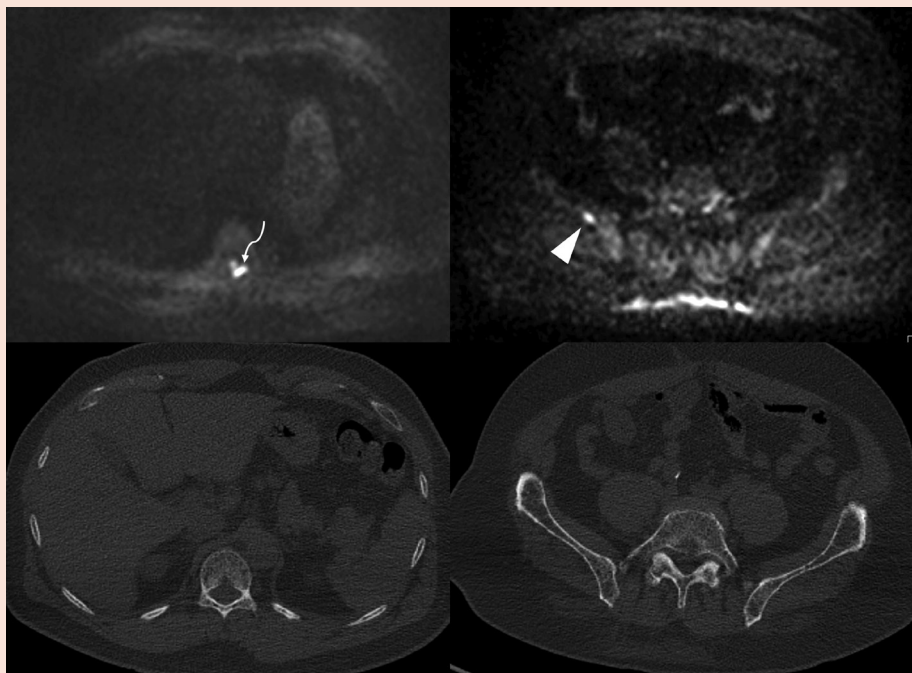


Fig. 5. (A) Diffusion-weighted imaging (DWI) in this patient demonstrated tiny lesions at the left lamina of T11 (arrow) and the right iliac wing (arrowhead) with no lytic change on the corresponding CT images. (B) Both axial positron emission tomography/computed tomography (PET/CT) and coronal PET/magnetic resonance (MR) demonstrate the dominant fluorodeoxyglucose-avid lesion involving the proximal right humerus (arrows) with lytic destruction of bone on CT imaging and a markedly hypointense marrow lesion on T1-weighted MR images.

(A)



(B)

